



Basic Principles of Inlay Arthroplasty in Type C Glenoid Dysplasia

Introduction:

Patients with a Type C glenoid deformity are uncommon in the orthopaedic practice, but present treatment challenges when conservative measures have failed (1,2) (Table 1). In order to effectively address these advanced changes in glenoid morphology, the surgeon must have a thorough understanding of the degree of anatomic change, including retroversion, degree of bone loss, and amount of humeral head displacement (3). Advanced diagnostic imaging, particularly CT is an important tool to evaluate glenoid bone stock and version (Figure 1). Clinical symptoms present as pain with limited external and internal rotation. The poor underlying bone quality and shallow glenoid vault pose difficulties for primary, revision and salvage procedures particularly in younger and active patients (Table 2). Long standing bony and soft tissue compensatory changes in these patients make advanced corrective procedures inadvisable as they increase the intraoperative risk, technical demands, and postoperative rehabilitation requirements.

The primary clinical goal is to resurface both sides of the joint as close as possible to the native anatomy, address primary pain generators and avoid the geometric mismatches associated with replacement or reconstruction procedures that could lead to early failures.

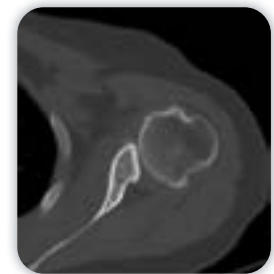

Figure 1:
Type C Glenoid.
Preoperative Axial CT

Table 1: Glenoid Classification (Walsh et al. 1999)






Type A1		Centered humeral head with minor erosion of the glenoid and loads equally distributed
Type A2		Centered humeral head with major central erosion of the glenoid and loads equally distributed
Type B1		Asymmetric distribution of loads with posterior subluxation of the humeral head, narrowing of the posterior joint space, subchondral sclerosis, and osteophytes
Type B2		Asymmetric distribution of loads with posterior subluxation of the humeral head and a biconcave glenoid
Type C		Dysplastic glenoid with >25° associated retroversion and a centered or slightly subluxed head

Table 2: Treatment Dilemma

Glenoid Bone Loss

- Limited Standard Glenoid Fixation
- Compromised Future Revision Options

Soft Tissue and Bony Compensation

- Correction Inadvisable

Young Age



Conventional Arthroplasty Options:

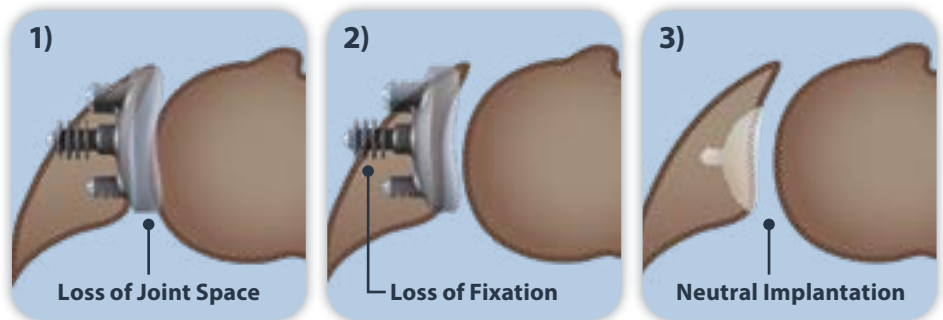
Following failed conservative care, patients with Type C glenoid may be suited for hemi-, total-, or reverse shoulder arthroplasty. Hemiarthroplasty remains limited since the glenoid defect is not addressed. Related results also do not seem to be influenced by the glenoid type since all stages may show progressive glenoid wear (1).

Total Shoulder Arthroplasty addresses glenohumeral deficiencies but increases the technical challenges for onlay glenoid implantation: The limited bone stock requires a balancing between joint volume changes and fixation strength and may require augmented bone grafting for adequate component fixation (Figure 2).

Reverse Total Shoulder Arthroplasty further increases the demand for glenoid bone stock and therefore may require substantial bone grafting augmented with an extra long central peg. Its use should be limited to patients over the age of 75 years.

Figure 2: Type C Glenoid. Comparison of Inlay/Onlay Component Placement:

- 1) High onlay placement with better fixation but loss of joint space
- 2) Low onlay placement with better joint volume but compromised fixation
- 3) Inlay placement with adequate fixation and unchanged joint volume



Patient Selection and Results:

Young and active patients, with a concentric humeral head centered on the glenoid, an intact rotator cuff, and glenoid based pathology may be suitable for inlay arthroplasty of the glenoid vault (Figure 2, 3). The procedure allows for improved component placement and retains additional bone stock for a single-stage revision. The implant provides an effective buttress for successful pain management while avoiding arthroplasty induced changes to the native anatomy and soft tissue envelope. In a case series of 9 shoulders with 2 years follow-up on patients treated for various levels of glenoid deficiency, Davis et al. reported a statistically significant increase in range of motion, decrease in pain scores, improvement in single assessment numeric evaluation, and patient satisfaction (4).

Surgical Tips and Pearls:

1. In order to level the glenoid, tilt the table away from the field
2. The 30 degree reaming and insertion technique facilitates glenoid vault access, preparation, and implantation
3. If possible, do not release the posterior capsule
4. Preserve a good quality, stable and hypertrophic posterior labrum
5. Do not remove posterior bone

Conclusion:

Larger cohorts and longer term follow-up is necessary to establish the clinical durability of inlay arthroplasty in Type C Glenoid deficient patients. However, supported by the complexity and challenges associated with alternative treatments, the procedure is a promising new direction for those select young and active patients whose primary symptoms are pain rather than function.

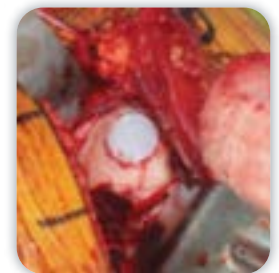


Figure 3: Type C Glenoid. Intraoperative HemiCAP Glenoid Component Placement

References:

1. Walch G, Badet R, Boulahia A, Khoury A. Morphologic study of the glenoid in primary glenohumeral osteoarthritis. J Arthroplasty. 1999 Sep;14(6):756-60.
2. Mansat P, Coutie A-S, Bonneville N., Rongieres M. Mansat M, Bonnevialle P. Resurfacing humeral prostheses: do we really reconstruct the anatomy? J Shoulder Elbow Res 2013 22(5): 612-619.
3. Sears BW, Johnston PS, Ramsey ML, Williams GR. Glenoid bone loss in total shoulder arthroplasty: evaluation and management. J Am Acad Orthop Surg. 2012 Sep;20(9):604-13.
4. Davis DE, Acevedo D, Williams A, Williams G. Total shoulder arthroplasty using an inlay mini-glenoid component for glenoid deficiency: a 2-year follow-up of 9 shoulders in 7 patients. J Shoulder Elbow Surg. 2016 Aug;25(8):1354-61.